

SORBACT® RESULTS IN FASTER WOUND HEALING AFTER PILONIDAL SINUS EXCISION

Dialkylcarbamoyl chloride-coated *versus* alginate dressings after pilonidal sinus excision: a randomized clinical trial (SORKYSA study)

BJS Open 2020; doi.org/10.1002/bjs.5.50259

B. Romain, M. Mielcarek, J.B. Delhorme, N. Meyer, C. Brigand, S. Rohr and the SORKYSA group

Departments of Digestive Surgery and Public Health, Strasbourg University Hospital, and Laboratory of Stress Response and Innovative Therapies, Institut National de la Santé et de la Recherche Médicale, University of Strasbourg, Strasbourg, France

Pilonidal sinus is, with an incidence rate of 26 per 100 000, a common disease near the natal cleft of the buttocks resulting from an infection of hair follicles. Young adult males are affected twice as often as females.

A common treatment is a surgical excision of the pilonidal sinus with the wound left open to heal by secondary intention. The drawback of this method is the lengthy healing process. New approaches that accelerate wound healing are of great value.

Study design: A multicentre, open, randomized controlled trial

Participants: 246 patients was conducted, 120 were treated with Sorbact® and 126 with Algostéril®

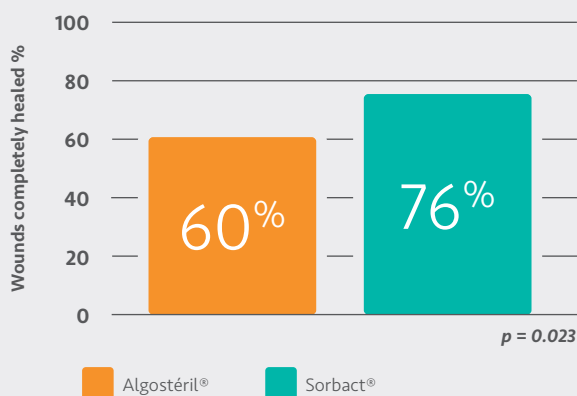
Aim: To compare Sorbact® Ribbon Gauze with Algostéril®

Primary endpoint: Wound healing 75 days after the operation

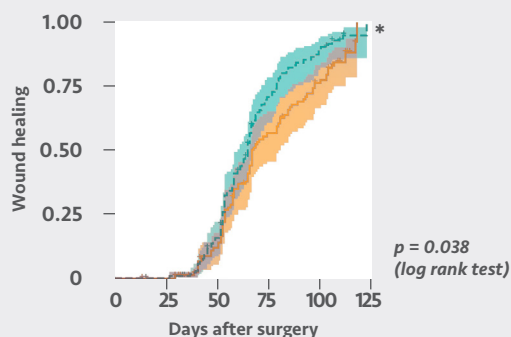
Secondary endpoints: Status of wound area among other fibrin and patients' assessments on qualities of the dressing and pain

Commercial involvement: None

GRAPH 1: Complete wound healing at 75 days



GRAPH 2: Difference in wound healing day 0 – 125



No. at risk	Algostéril®	110	108	91	45	27	3
	Sorbact®	112	111	95	34	14	1

* Kaplan-Meier analysis of cumulative incidence of wound healing after excision of pilonidal sinus, per-protocol analysis. Image has been modified, original image © 2020 The Authors. *BJS Open*.

The number of wounds completely healed was significantly higher for Sorbact®.

Patients assessed Sorbact® as comfortable to wear and their experience of pain during wear was low.

KEY FINDINGS

- The percentage of wounds completely healed at 75 days were significantly higher ($p = 0.023$) in the Sorbact® group as per-protocol analysis (graph 1).
- Significant difference ($p = 0.038$) in favor of Sorbact® was observed when wound healing over a longer period of time was analyzed using the Kaplan-Meier method as per-protocol analysis (graph 2).
- Less fibrin was observed on wounds with Sorbact® dressing ($p = 0.079$). Patients' assessments regarding comfort and pain during the day (VAS score lower than 1 of 10) were the same for both dressings.

The authors make a connection to results from earlier trials of using NPWT after pilonidal sinus excision and comment that "DACC-coated dressings (Sorbact®) could be a good alternative, either together with NPWT or alone, to increase the healing process of acute wounds".

DISCUSSION

The number of RCTs comparing the effectiveness of different dressings in patients with pilonidal sinus disease is very limited. This study shows that the use of Sorbact® results in faster wound healing compared to Algostéril®.